

# Intraoperative Dynamic Infrared Thermography and Free-Flap Surgery

Louis de Weerd, MD,\* James B. Mercer, PhD,†‡ and Line Bøe Setså†

**Abstract:** Flap failure in free-tissue transfer relates strongly to technical failure of the anastomosis or to kinking as well as to external compression of the donor or recipient vessels. Intraoperative monitoring of flap perfusion has shown to prevent flap failure. This prospective, clinical study presents the results of intraoperative dynamic infrared thermography as a novel method to monitor reperfusion indirectly in 10 free flaps. This noninvasive technique provided a fast and reliable method to register partial or total arterial occlusion due to anastomotic failure, as well as due to external compression or kinking of the vessels. The dynamic infrared image sequences showed an improved rate and pattern of rewarming of the flap after an additional venous anastomosis was opened. The state of reperfusion of the flap at the end of the operation could easily be determined. The authors conclude that dynamic infrared thermography provides the surgeon with valuable information on flap reperfusion during free flap surgery.

**Key Words:** reperfusion, free flap, dynamic infrared thermography

(*Ann Plast Surg* 2006;57: 279–284)

Free tissue transfer has become a reliable and well-established technique in reconstructive surgery. Success rates varying between 91% and 99%, with reexploration rates varying between 6% and 25% having been reported.<sup>1</sup> Successful outcome of the reexplorations appears to be inversely related to the time interval between the onset of ischemia and its recognition. Monitoring free flaps may keep this time interval as short as possible and therefore improve salvage rates.<sup>2–4</sup> Failure of free flaps has been reported to occur on the operating table during completion of the operation, rather than during the postoperative course.<sup>1,3,5–7</sup> Rosenbaum and Sundt<sup>8</sup> showed in

an animal model, that formation of an arterial thrombus following release of the clamps reaches maximum levels after 15 minutes. After 30 minutes, most of the thrombus has been lysed. A similar result was found by Boeckx et al<sup>9</sup> Primary thrombosis of one or both of the microsurgical anastomoses has been implicated as the predominant cause of free-flap failure. However, kinking or external compression of the flap pedicle or the recipient vessels can lead to secondary thrombosis postoperatively.<sup>10,11</sup> As a result, several authors have stressed the importance of intraoperative monitoring of free flaps. It is especially the period immediately after completion of the microsurgical anastomosis, as well as the period during inset and closure of the flap incisions, that is considered important to monitor.<sup>1,6,7</sup> Regardless of the experience of the surgeon, primary and secondary anastomotic thrombosis is an unavoidable potential complication. Any method that will rapidly identify reperfusion problems in free flaps will increase the likelihood that flap salvage is possible. This rapidity is accomplished by clinical assessment, objective data being provided by the monitoring technique, or a combination of both.

Clinical monitoring of flaps relies on skin color, capillary refill, and turgor to provide visual evidence of flap perfusion. Recognizing the visual cues of a failing flap early enough to successfully salvage the tissue requires considerable clinical experience. Some flaps, such as the free groin flap and the free musculocutaneous latissimus dorsi flap, are notorious for appearing very pale during the initial postanastomotic period. In dark-skinned patients, deep pigmentation masks changes in capillary refill and color. A number of monitoring techniques have been devised to facilitate the early detection of poor flap perfusion, allowing prompt surgical intervention where necessary. Salmi et al<sup>12</sup> reported on the use of infrared (IR) thermography for intra- and postoperative monitoring of free TRAM flaps. IR thermography is widely used in clinical medicine as a noninvasive technique to measure skin temperature.<sup>13</sup> The correlation between thermographic and laser Doppler velocimetric results is good.<sup>14</sup> Dynamic IR thermography is based on the relationship between dermal perfusion and the rate of change in skin surface temperature following transient thermal challenges.<sup>15,16</sup> The technique has been used to locate perforators and to assist in flap design.<sup>13,17,18</sup> This study evaluates intraoperative dynamic IR thermography as a novel method to indirectly monitor flap reperfusion during breast reconstruction with the deep inferior epigastric artery perforator (DIEP) flap and the superficial inferior epigastric artery (SIEA) flap. The rate and pattern of rewarming after the cold challenge during primary

Received December 28, 2005, and accepted for publication February 22, 2006.

From the \*Department of Plastic Surgery and Hand Surgery and †Department of Radiology, University Hospital North Norway, Tromsø, Norway; and ‡Department of Medical Physiology, Faculty of Medicine, University of Tromsø, Tromsø, Norway.

No sources of financial support.

Reprints: Louis de Weerd, Department of Plastic Surgery and Hand Surgery, University Hospital North Norway, N 9038 Tromsø, Norway. E-mail: louis.deweerd@unn.no.

Copyright © 2006 by Lippincott Williams & Wilkins

ISSN: 0148-7043/06/5703-0279

DOI: 10.1097/01.sap.0000218579.17185.c9

ischemia and after a cold challenge at the end of the operation were investigated. The effect of an additional venous drainage route on flap reperfusion is also highlighted.

## MATERIALS AND METHODS

Ten patients, mean age 49.5 years (range, 34–59 years) and a mean body mass index 25.3 kg/m<sup>2</sup> (range 20.2–30.5 kg/m<sup>2</sup>) participated in this prospective study. All patients were scheduled for a secondary breast reconstruction with either a free DIEP flap or a free SIEA flap. On the preoperative day, arterial perforator sounds were located with a handheld Doppler (8MH, Multi Dopplex II, Huntleigh Healthcare, Cardiff, UK) on the lower abdomen and marked with a permanent marker on the skin. Preoperative IR thermal images of the abdomen were taken after an acclimatization period of 20 minutes at room temperature, as well as during rewarming after a local cold challenge. During the operation, sequences of digital IR thermal images of the free flap were taken:

- just before clamp release,
- just after clamp release,
- in 4 cases after an extra venous anastomosis was performed, and
- in 3 cases after a local cold challenge with a metal plate at room temperature at the end of the operation.

A Nikon Laird S270 (Tokyo, Japan) IR camera was used for monitoring skin surface temperatures. This camera is capable of producing sequences of high-definition digital IR images. All IR images were electronically stored and afterward processed using image analysis software PicWin-IRIS (EBS System Technik GmbH, München, Germany). An accuracy of 0.1°C in measurements was obtained. IR thermal images were taken at regular intervals to register the rate and pattern of the rewarming. At the end of the operation, an arterial perforator sound was located on the flap with the handheld Doppler and this site was marked with a suture. The presence and location of this sound, as well as the clinical

evaluation of the flap by color, turgor, capillary refill, and temperature, were recorded. All flaps were anastomosed to the internal mammary vessels. In case of an extravenous anastomosis, the contralateral superficial inferior epigastric vein (SIEV) was anastomosed to the cephalic vein.

## RESULTS

Table 1 shows information on each patient and her operation. Comparison of the preoperative digital IR images with those taken just before clamp release showed, in all cases, that the skin temperature of the lower abdominal flap fell dramatically when not perfused. Six flaps (patients 1, 2, 4, 5, 6, 9) showed a rapid appearance of a “hot spot” after clamp release, followed by more hot spots and a general rewarming of the flap. Figure 1 illustrates such a case.

In 2 flaps (patients 8, 9), the rate of skin rewarming was low, and in particular, the appearance of hot spots was less evident. The flaps rewarmed slowly around the hot spot, but no general rewarming was seen. Clinical evaluation of the flap was indicative for poor reperfusion of the flap.

In patient 8, kinking of the pedicle was the cause of reperfusion problems. Both pattern and rate of rewarming improved dramatically after the pedicle was repositioned, followed by a clinical improvement in reperfusion.

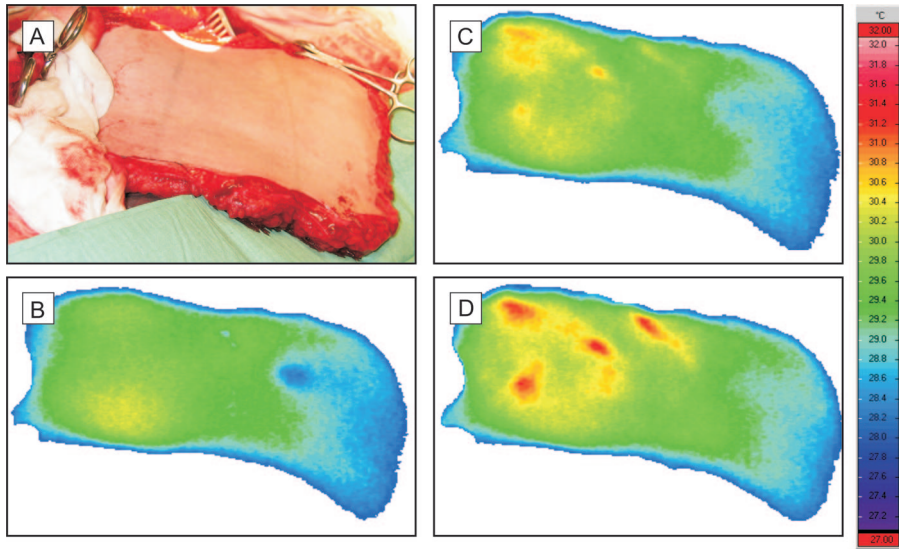
In patient 9, external compression of the pedicle by a surgical instrument resulted in a poorly reperfused flap. Removal of the instrument caused the rapid appearance of a well-defined hot spot, followed by a general rewarming of the flap (Fig. 2). Also clinically, there was an improved reperfusion of the flap, although it was registered after the improvement on the IR thermal images was seen.

In patients 3 and 10, no rewarming was seen after clamp release. In patient 3, an intima lesion in the internal mammary artery had caused a proximally located arterial thrombosis. No improvement was seen after resection of the affected part and reanastomosis, most probably due to thrombus release into the flap. In patient 10, an inadvertent damage to the perforator was diagnosed as the cause of flap failure.

**TABLE 1.** Individual Patient Information, Including Operative Data

Patient	Age, yr	BMI	RT	FLAP	FW	OT	PIT	AVA	D1	D2	K/EC	OR
1	56	23.9	+	SIEA	476	5 h 52 m	69	+	+	–	–	+
2	59	25.4	–	DIEP	700	5 h 43 m	53	+	+	–	–	+
3	56	29.1	+	DIEP	?	5 h 30 m	65	+	+	–	–	–
4	34	20.2	–	DIEP	560	5 h 50 m	53	+	+	–	–	+
5	36	30.5	–	DIEP	1104	6 h 5 m	25	+	+	–	–	+
6	53	23.7	–	SIEA	430	6 h 18 m	58	–	+	–	–	+
7	52	24.3	+	DIEP	804	6 h 5 m	45	+	+	+	–	+
8	52	24.8	–	SIEA	540	5 h 37 m	60	+	+	+	K	+
9	41	30.1	+	DIEP	900	5 h 50 m	45	+	+	+	EC	+
10	55	21.1	–	DIEP	503	8 h 20 m	–	–	+	–	–	–
Mean	49.5	25.3			669	6 h 7 m	53					
±SD	9.0	3.6			227	0 h 48 m	13					

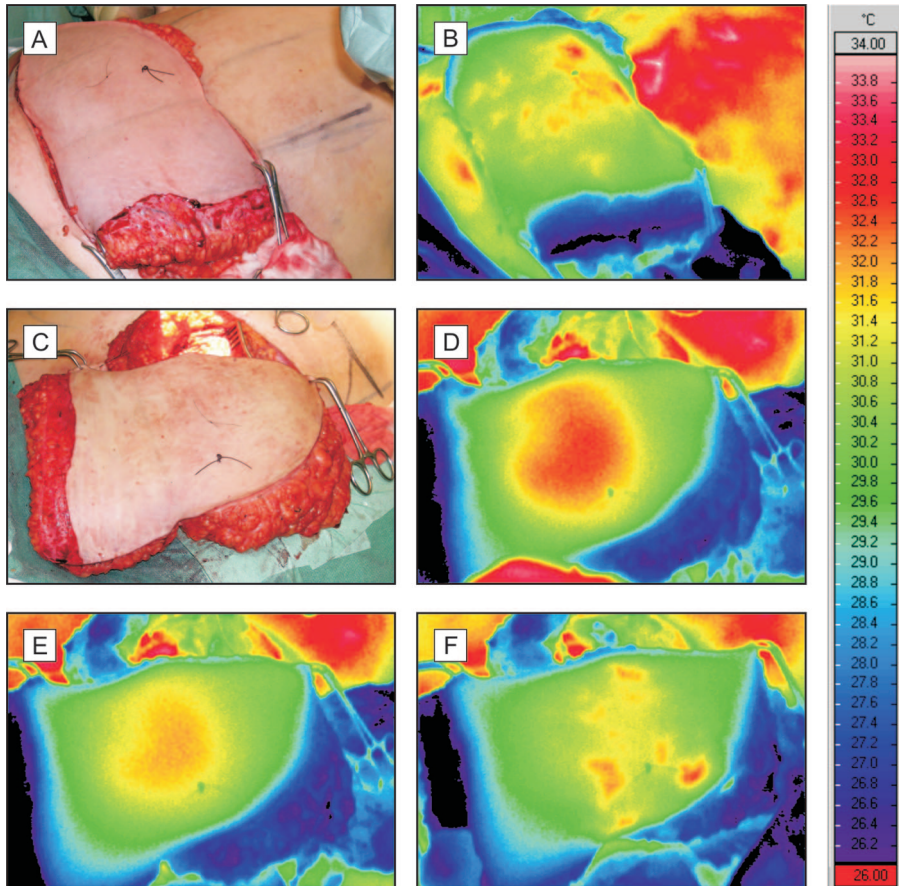
BMI indicates body mass index; RT, previous treatment with radio therapy (– = none; + = received); FLAP, flap type (SIEA, superficial inferior epigastric artery; DIEP, deep inferior epigastric artery); FW, flap weight (g); OT, operation time (hours and minutes); PIT, primary ischemic time (minutes); AVA, additional venous anastomosis (+ = yes; – = no); D1, dynamic infrared thermography performed during opening primary anastomosis (+ = yes; – = no); D2, dynamic infrared thermography performed with applied cold challenge (+ = yes; – = no); K/EC, kinking (K) or external compression (EC); OR, operation result (+ = successful; – = unsuccessful), mean ± SD (standard deviation).



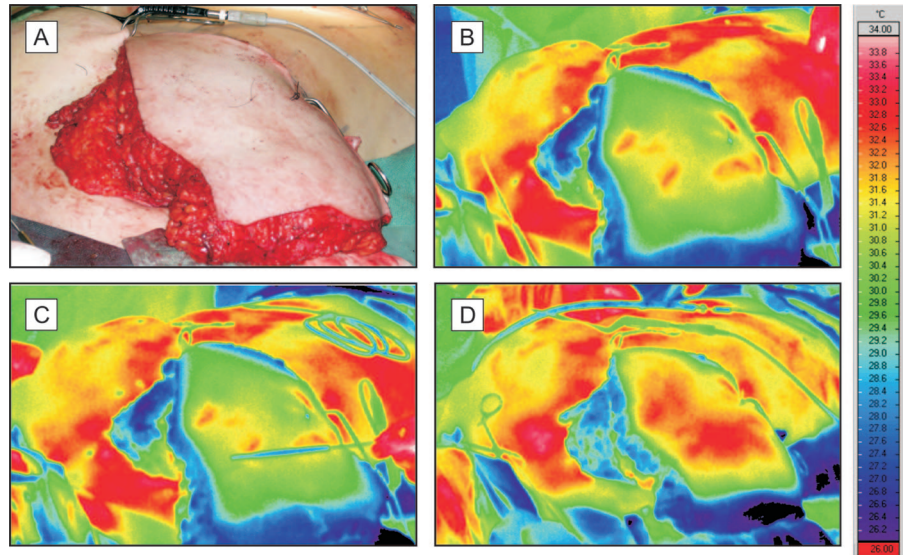
**FIGURE 1.** A, Digital photograph of a free DIEP flap. B–D, Sequence of infrared thermal images illustrating a successful rewarming of a free DIEP flap after completion of the microsurgical anastomosis. B is taken at the moment of clamp release, C is taken 2 minutes after clamp release and D is taken 4 minutes after clamp release. Note the rapid appearance of hot spots in C and D.

In patients 5, 7, 8, and 9 the overall rewarming pattern improved dramatically after opening of an extravenuous anastomosis (Fig. 3). Dynamic IR thermography was performed on the flaps of patients 7, 8, and 9 after flap modeling and inset were completed. After contact cooling with the metal plate, all flaps showed a rapid rewarming of the whole flap. A typical case is

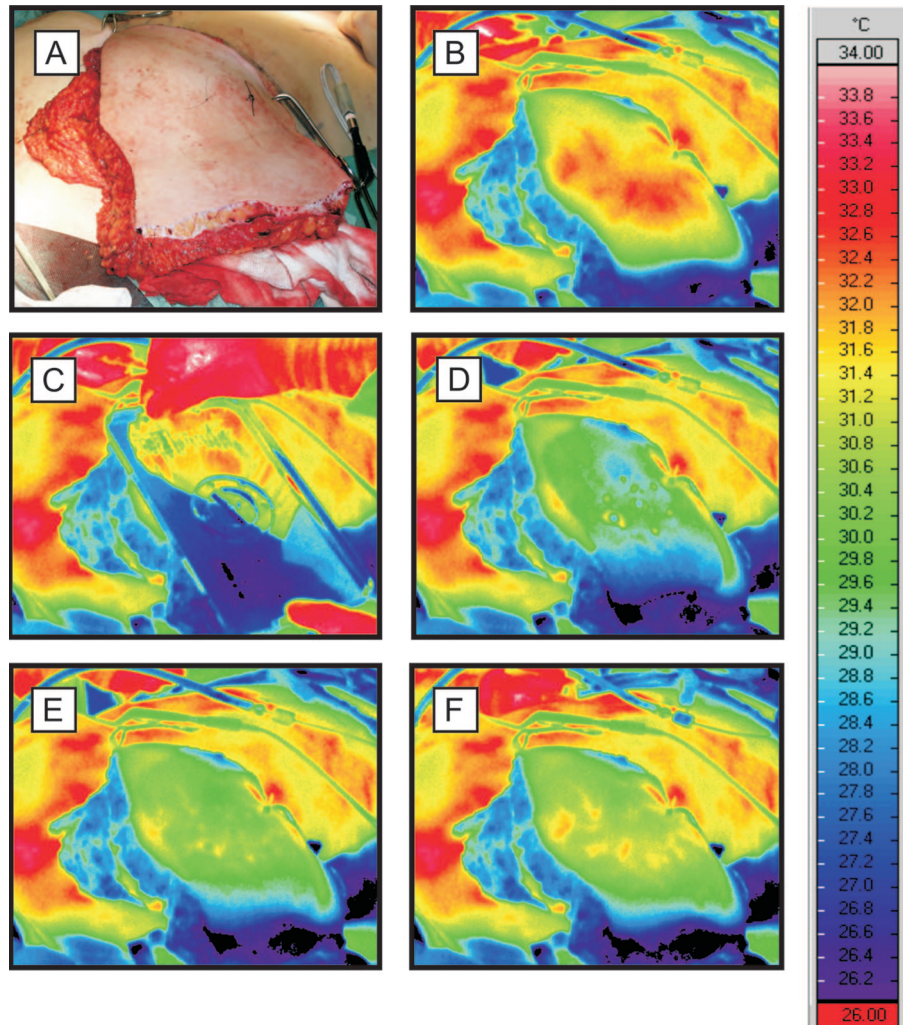
shown in Figure 4. Of those flaps that survived, the location of the first appearing hot spot correlated well with the location of the arterial Doppler sound. In all cases, the registration of the hot spot with IR thermography preceded the registration of the Doppler sound. In 2 cases, the arterial Doppler sound could be heard only first after completion of the operation.



**FIGURE 2.** A, Digital photograph and B, infrared thermal image of a free DIEP flap at the donor site and perfused by one single perforator. C, Digital photograph and D, infrared thermal image after successful completion of the anastomosis to the mammary vessels. Note the uniform thermal pattern in D, with further cooling in E as a result of compression of the pedicle to the flap. F shows rewarming of the flap with rapid return of the hot spots following relief of the compression.



**FIGURE 3.** A, Digital photograph of a DIEP flap. B and C show infrared thermal images of the same flap after successful microsurgical anastomosis. The straight line in C indicates the linea alba. The thermal image in D was taken some minutes after a second vein had been anastomosed to improve flap drainage. Note the improved rewarming of the flap.



**FIGURE 4.** A, Digital photograph of a DIEP flap after a successful anastomosis to the mammary vessels. B–F, show a sequence of IR thermal images illustrating dynamic IR thermography after a cold challenge to the flap with a metal plate. The thermal image in B was taken prior to the cooling. The rewarming sequence D–F was taken over a period of 3 minutes. Note the rapid return of hot spots.

## DISCUSSION

Most clinical studies evaluating monitoring techniques for free tissue transfer deal with the postoperative period. However, Jones<sup>1</sup> attributed the high success rate and low reexploration rate after free tissue transfer in their series directly to intraoperative monitoring. Intraoperative monitoring may inform the surgeon on patency of the anastomosis and detect kinking or external compression of the flap pedicle or recipient vessels during flap inset.

We have successfully used dynamic IR thermography as a novel method for intraoperative monitoring reperfusion of free DIEP and free SIEA flaps during breast reconstruction. This technique involves the registration of skin temperatures with an IR camera before and after exposure of tissue to a thermal challenge. During primary ischemia, the nonperfused free flap cools down during its exposure to room temperature. This is the first thermal challenge to the free flap. In successful free flap transfer, the temperature of the flap reaches its lowest value just before release of the microvascular clamps. The advantage of using the DIEP flap in this study is the well-defined entrance point of the perforator into this flap. Rapid rewarming of the flap after the cold challenge during primary ischemia has to start here. The dynamics of rewarming, shown by its rate and pattern, were easily registered with the IR camera. The rapid appearance of a hot spot on the flap clearly indicates where the rewarming starts. The dissection of the DIEP flap requires microsurgical skills to prevent inadvertent damage to the perforator. One DIEP flap showed no rewarming and was lost due to a damaged perforator. Although the SIEA flap is not considered a perforator flap,<sup>19,20</sup> the IR camera also registered hot spots after release of the clamps. These hot spots coincided with the locations where arterial Doppler sounds were heard, a phenomenon similar to that seen with DIEP flaps. The registration of a hot spot preceded in all cases the registration of an arterial Doppler sound. In some cases, the arterial Doppler sound could only first be registered postoperatively, causing uncertainty over the state of flap perfusion. It is apparent from this study that the anatomic structure related to a hot spot must be a perforator.

No venous thrombosis was encountered in this study. Thrombosis at the venous anastomotic site has become rare since we are using a microvascular venous coupling device, which is in accordance with reports of others.<sup>21,22</sup> In 8 of 10 patients, 2 veins drained each flap, with the second venous anastomosis being the one between the contralateral SIEV to the cephalic vein. Opening this second route of venous drainage was associated with an improved rate and pattern of rewarming of the flap. Clinical signs of venous congestion were reduced dramatically after opening of the second venous anastomosis but were always preceded by the improved rewarming that was clearly seen on the IR images. It is likely that an increase of venous drainage improves the overall reperfusion of the flap.<sup>23,24</sup> However, Gill et al<sup>21</sup> found in their retrospective review of DIEP flaps for breast reconstruction that venous congestion was statistically unrelated to the number of venous anastomoses.

During flap modeling and inset, reperfusion problems may occur either due to kinking or external compression or to thrombosis of the anastomosis. These reperfusion problems

can occur in a flap that has already become partially rewarmed. Diagnosing such a reperfusion problem from static IR thermal images may be difficult and time consuming. A partially rewarmed flap with reperfusion problems cools by conductive and radiative heat loss as there is no optimal heat transport by blood. The rate of heat change may therefore be low. Exposing the flap to a cold challenge, as in dynamic IR thermography, provides the surgeon with information on the rapidity of rewarming, as well as on the pattern of rewarming. The results from this study showed that a fast and overall rewarming of a free flap is most likely with adequate arterial inflow and venous drainage. In 3 patients, dynamic IR thermography was used at the end of the operation to confirm successfully reperfusion of the flap.

Two patients out of 10 showed reperfusion problems, one due to kinking and one due to external compression of the feeding vessels. Both flaps showed a poor rewarming in rate, as well as in pattern. A dramatic improvement in the thermal picture was seen following correction of these causes, before clinical signs of improvement were seen.

The intraoperative use of dynamic IR thermography registered successful arterial inflow, as well as partial and total obstruction of arterial inflow. It is especially the former which may be clinically difficult to detect. Such information may be vital for flap survival. The profound improvement in rate and pattern of rewarming with an additional venous anastomosis justifies its use in free DIEP and SIEA flaps. In this study, dynamic IR thermography was used on skin flaps, but it is likely that this technique will be useful to monitor other types of flaps as well. Although further research is necessary, dynamic IR thermography appears to be a valuable method for intraoperative monitoring of free tissue transfer.

## ACKNOWLEDGMENTS

The authors thank Mr. Knut Steinnes, Department of Medical Physiology, Faculty of Medicine, University of Tromsø, Norway for assistance in preparing the figures.

## REFERENCES

1. Jones NF. Intraoperative and postoperative monitoring of microsurgical free tissue transfers. *Clin Plast Surg*. 1992;19:783-797.
2. Disa J, Cordeiro PG, Hidalgo DA. Efficacy of conventional monitoring techniques in free tissue transfer: an 11-year experience in 750 consecutive cases. *Plast Reconstr Surg*. 1999;104:97-101.
3. Kind GM, Buntic RF, Buncke GM, et al. The effect of an implantable Doppler probe on the salvage of microvascular tissue transplants. *Plast Reconstr Surg*. 1998;101:1268-1273.
4. Brown JS, Devine JC, Magennis P, et al. Factors that influence the outcome of salvage in free tissue transfer. *Br J Oral Maxillofac Surg*. 2003;41:16-20.
5. Schecker LR, Slattery PG, Firrell JC, et al. The value of the photoplethysmograph in monitoring skin closure in microsurgery. *J Reconstr Microsurg*. 1985;2:1-5.
6. Holm C, Tegeler J, Mayr M, et al. Monitoring free flaps using laser-induced fluorescence of indocyanine green: a preliminary experience. *Microsurgery*. 2002;22:278-287.
7. Mothes H, Dönicke T, Friedel R, et al. Indocyanine-green fluorescence video angiography used clinically to evaluate tissue perfusion in microsurgery. *J Trauma*. 2004;57:1018-1024.
8. Rosenbaum TJ, Sundt TM. Thrombus formation and endothelial alterations in microarterial anastomoses. *J Neurosurg*. 1997;47:430-441.

9. Boeckx WD, Haribhakti VV, Bosmans L. Scanning electron microscopic study of thrombus formation in an end-to-side anastomosis of the rat carotid artery. *J Reconstr Microsurg*. 1994;10:35–38.
10. Khouri RK. Avoiding free flap failure. *Clin Plast Surg*. 1992;19:773–781.
11. Ozbek MR, Deune EG, Cooley BC, et al. Experimental reproduction of free flap errors: a new model of thrombosis. *Ann Plast Surg*. 1994;32:474–477.
12. Salmi AM, Tukiainen E, Asko-Seljavaara A. Thermographic mapping of perforators and skin blood flow in the free transverse rectus abdominis musculocutaneous flap. *Ann Plast Surg*. 1995;35:159–164.
13. Ammer K, Ring JF. *The Thermal Image in Medicine and Biology*. Wien: Uhlen-Verlag; 1995.
14. Mercer JB, de Weerd L. The effect of water-filtered infrared-A (wIRA) irradiation on skin temperature and skin blood flow as evaluated by infrared thermography and scanning laser Doppler imaging. *Thermol Int*. 2005;15:89–94.
15. Francis JE, Roggli R, Love TJ. Thermography as a means of blood perfusion measurements. *J Biomech Eng*. 1979;101:246–249.
16. Wilson SB, Spence VA. Dynamic thermographic imaging method for quantifying dermal perfusion: potential and limitations. *Med Biol Eng Comput*. 1989;27:496–501.
17. Theuvenet WJ, Koeyers GF, Borghouts MHM. Thermographic assessment of perforating arteries. *Scand J Plast Reconstr Surg*. 1986;20:25–29.
18. Itoh Y, Arai K. Use of recovery-enhanced thermography to localize cutaneous perforators. *Ann Plast Surg*. 1995;34:507–511.
19. Blondeel PN, Van Landuyt KHI, Monstrey SJM, et al. The “Gent” consensus on perforator flap terminology: preliminary definitions. *Plast Reconstr Surg*. 2003;112:1378–1382.
20. Kim JT. New nomenclature concept of perforator flap. *Br J Plast Surg*. 2005;58:431–440.
21. Gill PS, Hunt JP, Guerra AB, et al. A 10-year retrospective review of 758 DIEP flaps for breast reconstruction. *Plast Reconstr Surg*. 2004;113:1153–1160.
22. Sullivan SK, Dellacroce F, Allen R. Management of significant venous discrepancy with microvascular venous coupler. *J Reconstr Microsurg*. 2003;19:377–380.
23. Ichinose A, Terashi H, Nakahara M, et al. Do multiple venous anastomoses reduce risk of thrombosis in free-flap transfer? *Ann Plast Surg*. 2004;52:61–63.
24. Hallock GG, Rice DC. Efficacy of venous superdrainage of the deep inferior epigastric perforator flap in a rat model. *Plast Reconstr Surg*. 2005;116:551–555.